

Cluster 1
Small/normal cavity
Increase or normal global contractility

Phenotype 1	Phenotype 2	Phenotype 3
<p>Small cavity</p>	<p>Normal</p>	<p>LA dilation, LVH thick septum</p>
<p>Flat IVC</p>	<p>Collapsing IVC</p>	<p>Collapsing IVC</p>
<p>Lungs - A pattern</p>	<p>Lungs - A pattern</p>	<p>Lungs - A pattern</p>

1	2	3
Hypovolemic shock	Distributive shock	Diastolic dysfunction +/- Hypovolemic +/- Distributive shock

Cluster 2
Enlarged LV +/- RV cavity
Decreased global contractility

Phenotype 4	Phenotype 5
<p>LA & LV dilation</p>	<p>Bi A, Bi V dilation</p>
<p>Plethoric IVC</p>	<p>Plethoric IVC</p>
<p>Lungs - B pattern</p>	<p>Lungs - B pattern</p>

4	5
Cardiogenic shock (pump failure) high pressure pulmonary edema	

Cluster 3
Isolated enlarged right ventricle
Increase or normal LV contractility

Phenotype 6	Phenotype 7
<p>RV dilation, no RVH</p>	<p>RV dilation, RVH</p>
<p>Plethoric IVC</p>	<p>Plethoric IVC</p>
<p>Lungs - A B pattern</p>	<p>Lungs - A B pattern</p>

6	7
Acute isolated RV failure ARDS	Acute on chronic isolated RV failure ARDS pulmonary HTN

EASy phenotypes are based on the subcostal four-chamber view (top row), subcostal IVC view (middle row), and lung evaluation in the upper lung fields (bottom row).

Phenotypes 1 to 3 are grouped within cluster 1, phenotypes 4 and 5 are part of cluster 2, and phenotypes 6 and 7 are part of cluster 3. In general, cardiac assessment assesses myocardial performance, IVC evaluation provides the estimate of fluid responsiveness, and lung examination defines fluid tolerance (A-profile) and intolerance (B-profile).

- **Phenotype 1** describes the patient with hypovolemic shock with small diastolic ventricular chamber size, collapsed IVC with significant variability in its diameter throughout the respiratory cycle, and A-profile on lung examination.
- **Phenotype 2** is consistent with distributive shock in adequately fluid resuscitated patient with good cardiac filling, normal IVC size, and A-profile on lung examination.
- **Phenotype 3** describes patient with hypertrophic LV, commonly dilated left atrium, small and collapsible IVC, and A-profile on lung examination.
- **Phenotypes 4 and 5** describe patient with isolated LV (phenotype 4) and biventricular (phenotype 5) dysfunction, usually plethoric IVC and B-profile on lung examination.
- **Phenotype 6** most commonly describes patient with ARDS complicated by RV dysfunction. These patients demonstrate enlarged RV, plethoric IVC, and B-profile on lung examination more commonly reflecting nonhydrostatic edema.
- **Phenotype 7** includes patients with underlying pulmonary hypertension and RV hypertrophy who develop acute on chronic RV failure. These patients have enlarged and hypertrophic RV, plethoric IVC, and variable lung profile (B-profile shown here).




Bi A, Bi atrial; Bi V, Bi ventricular; HTN, hypertension; LA, left atrium; LVH, left ventricular hypertrophy; RA, right atrium; RVH, right ventricular hypertrophy.

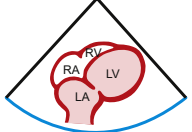

Source: Bughrara, N., Diaz-Gomez, J. L. & Pustavoitau, A. Perioperative Management of Patients with Sepsis and Septic Shock, Part II: Ultrasound Support for Resuscitation. *Anesthesiol Clin* 38, 123–134 (2020).

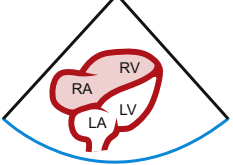
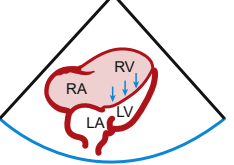
Cluster ①

Cluster ②

Cluster ③

1	3	2
Small cavity	LA dilation, LVH thick septum	Normal
		

4	5
LA & LV dilation	Bi A, Bi V dilation
	

No septal shift → LV	Septal shift
	

10 ml/kg IVF challenge
Volume
NE
Vasopressin phenylephrine

5 ml/kg IVF challenge
NE ± Vasopressin
Inotropic agent(s)

2.5 ml/kg IVF challenge	No volume
Vasopressin	Vasopressin
Inotropic agent(s)	Inotropic agent(s)

PPV is accurate and could be used if the following is met:
Passive ventilation with no effort,
TV > 8, RR < 30, sinus rhythm,
no RV failure, closed chest

PPV might not be accurate

PPV is not accurate in case of RV failure, do not follow

Organization of ultrasound findings into phenotypes and clusters allows providers to develop a systematic approach to patient optimization immediately before induction of anesthesia.

The mainstay therapy for patients in **cluster 1** includes fluid resuscitation, and as the inferior vena cava becomes fuller and interstitial B-line pattern appears on lung examination the therapy shifts toward vasoactive medications. These patients could be followed in the operating room using serial EASy examination and pulse pressure variation.

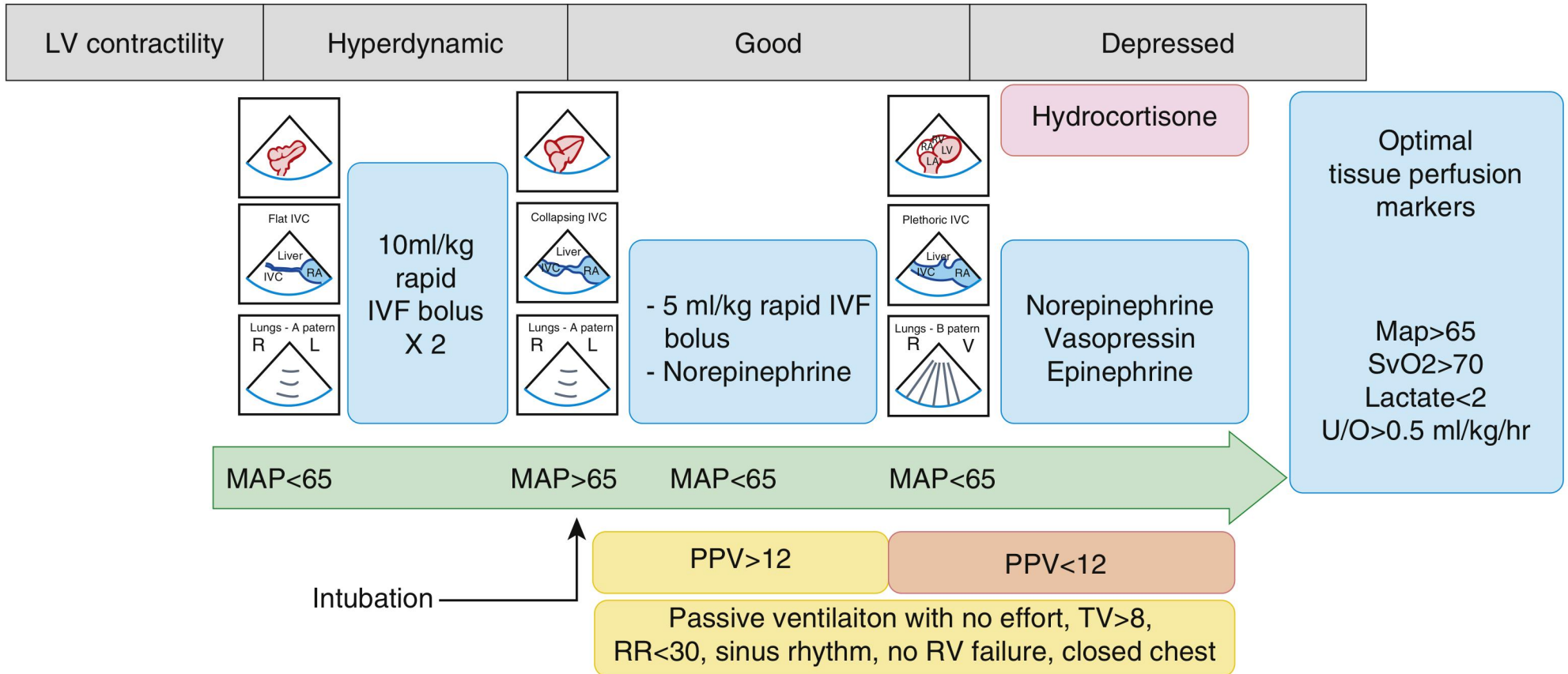
Depending on IVC evaluation and lung examination patients in **cluster 2** may benefit from small titrated fluid boluses 2.5 to 5 mL/kg (under conditions of collapsible IVC, A-profile on lung examination); however, the mainstay therapy usually consists of using vasoactive medications and occasionally inotropic agents when end-organ perfusion is not restored. In these patients, pulse pressure variation is of value, and additional evaluation of LV diastolic function if appropriate expert is available.

Patients in **cluster 3** present particular challenges, and assessment of septal shift is required to establish whether RV function is compensated (septum does not bow into the LV during diastole allowing for adequate LV filling) or not. Gentle fluid loading on a scale of 2.5 mL/kg can be provided when function is compensated, and such measures as diuresis or renal-replacement therapy undertaken when RV function is decompensated. The mainstay therapy includes maintenance of systemic blood pressure with vasoactive medications and inotropic support and minimizing increases in pulmonary pressures by avoiding hypoxemia/hypercapnea and through the use of pulmonary vasodilators.

IVF, intravenous fluid; NE, norepinephrine.

Source: Bughrara, N., Diaz-Gomez, J. L. & Pustavoitau, A. Perioperative Management of Patients with Sepsis and Septic Shock, Part II: Ultrasound Support for Resuscitation. *Anesthesiol Clin* 38, 123–134 (2020).

Septic shock patient presented to OR for surgical source control
 Phenotype 1 progressing to phenotypes 2 and 4

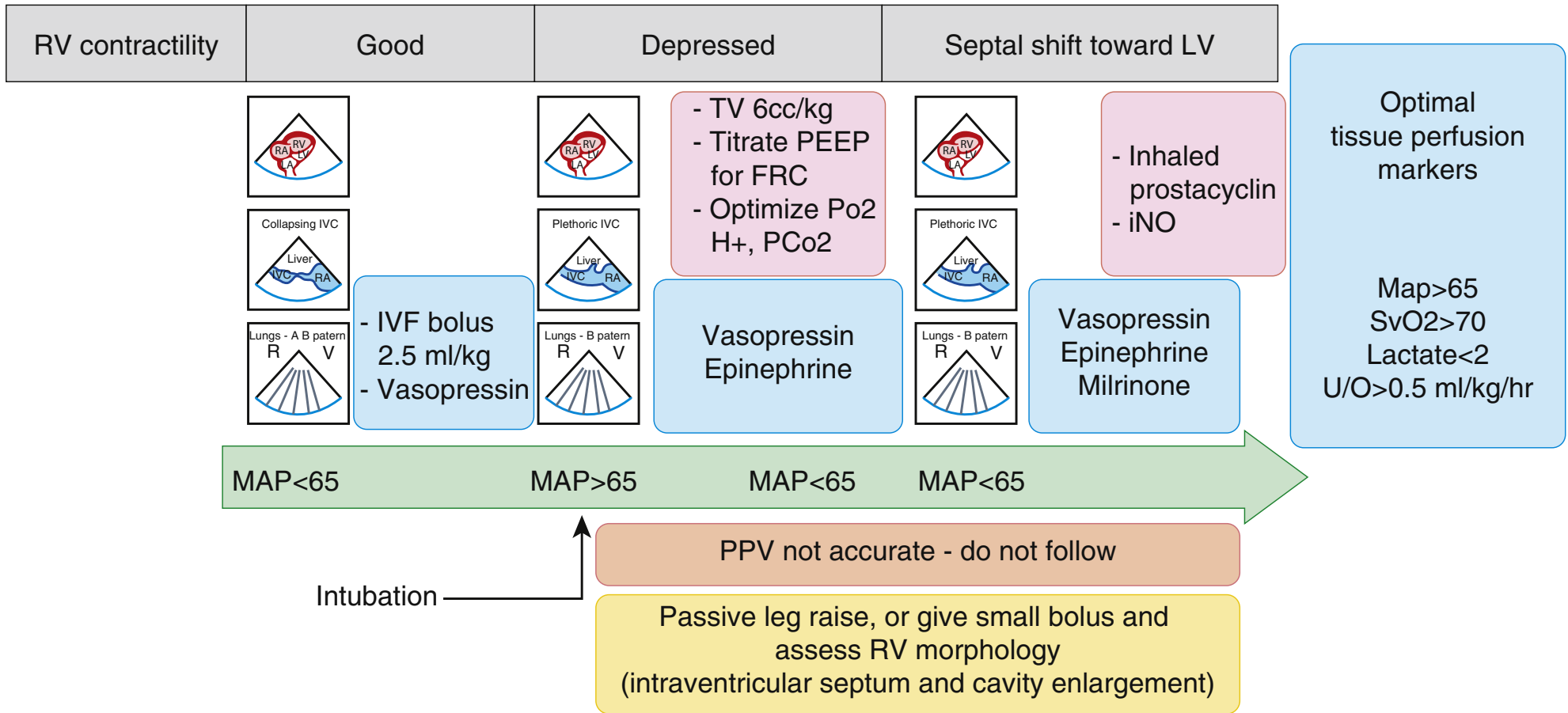


Example of progressive resuscitation and serial evaluation of a patient with septic shock who presented to the operating room initially demonstrating phenotype 1. Accordingly, the patient received fluid boluses 10 mL/kg at a time until he demonstrated phenotype 2 and systemic mean arterial pressure was greater than 65 mm Hg. After intubation and initiation of positive pressure ventilation, pulse pressure variation was used to guide further fluid therapy in addition to serial EASy examinations. Norepinephrine was added because of persistent hypotension. When patient developed left ventricular dysfunction, plethoric inferior vena cava, and interstitial edema pattern on lung examination (phenotype 4), fluid was halted and epinephrine added; additional metabolic support with hydrocortisone was offered. In accordance with Surviving Sepsis Guidelines tissue perfusion markers were followed throughout the case, and goals of resuscitation are stated in the box on the far right.

MAP, mean arterial pressure; OR, operating room; PPV, pulse pressure variation; RR, respiratory rate; TV, tidal volume.

Source: Bughrara, N., Diaz-Gomez, J. L. & Pustavoitau, A. Perioperative Management of Patients with Sepsis and Septic Shock, Part II: Ultrasound Support for Resuscitation. *Anesthesiol Clin* 38, 123–134 (2020).

Phenotype 7 (Septic shock/preexisting pulmonary HTN/ARDS)

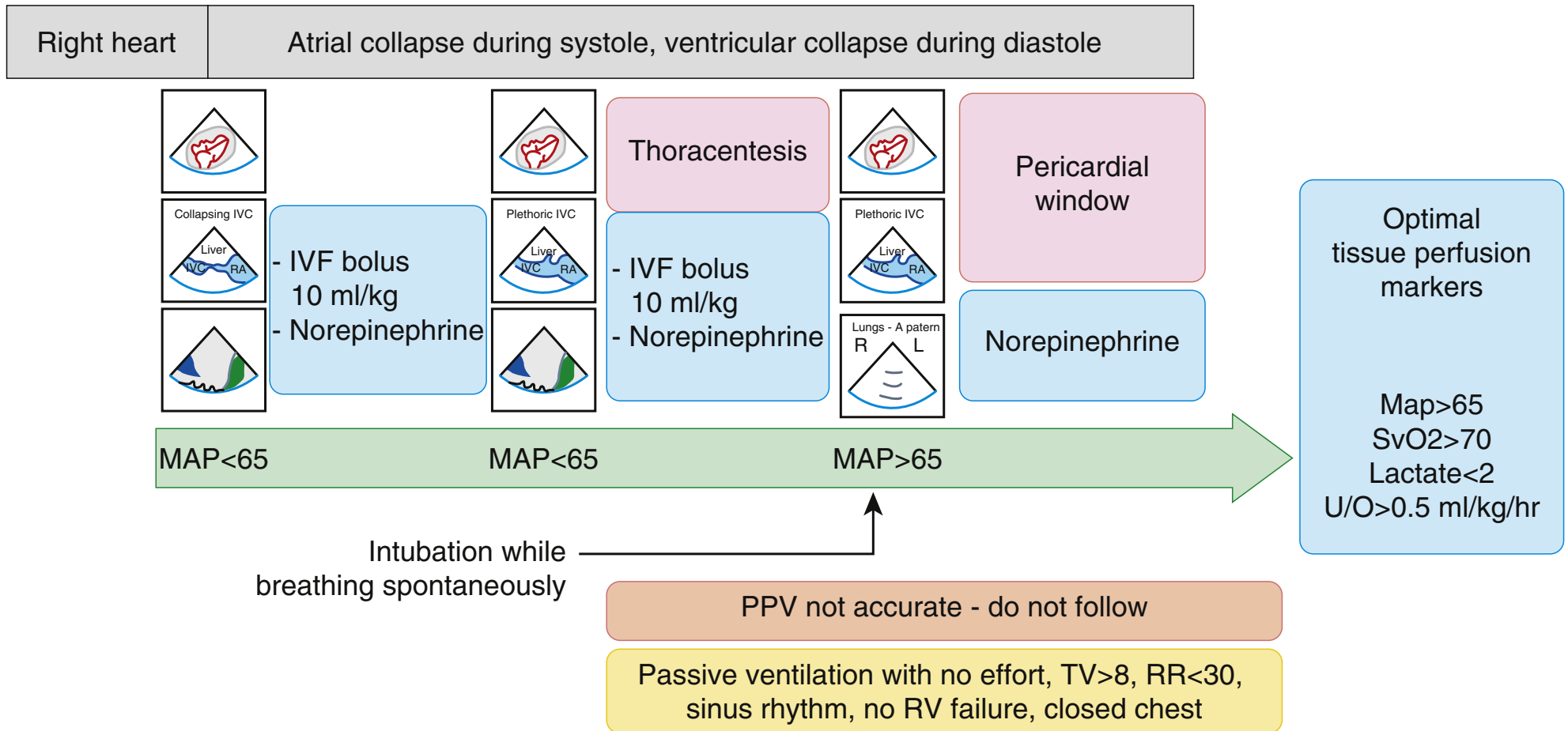


Example of resuscitation of a patient with preexisting pulmonary hypertension with RV hypertrophy who developed ARDS and septic shock (phenotype 7). Initially, small fluid boluses 2.5mL/kg at a time were provided until inferior vena cava became fuller and systemic mean arterial pressure improved to greater than 65 mm Hg. On induction of anesthesia, intubation, and initiation of positive-pressure ventilation using protective strategy with low tidal volumes and titrated positive end-expiratory pressure and fraction of inspired oxygen, RV function became decompensated with bowing of interventricular septum through cardiac cycle toward the left ventricle. At this point vasoactive medications (vasopressin) and inotropic (epinephrine and milrinone) were added and patient was started on pulmonary vasodilator (inhaled prostacyclin). Pulse pressure variation readings are inaccurate in a patient with decompensated RV function and was not followed. In accordance with Surviving Sepsis Guidelines tissue perfusion markers were followed throughout the case, and goals of resuscitation are stated in the box on the far right.

FRC, functional residual capacity; PEEP, positive end-expiratory pressure.

Source: Bughrara, N., Diaz-Gomez, J. L. & Pustavoitau, A. Perioperative Management of Patients with Sepsis and Septic Shock, Part II: Ultrasound Support for Resuscitation. *Anesthesiol Clin* 38, 123–134 (2020).

Phenotype 8 (pericardial tamponade, large pleural effusion)



Although not included in this classification of hemodynamic phenotypes, obstructive physiology is occasionally present in patients with septic shock, and large pleural effusions confound clinical presentation of these patients. In this example, patient presented with pericardial and large pleural effusion; however, still flat and collapsible IVC. He received titrated 10 mL/kg fluid boluses and vasoactive support with norepinephrine until IVC became fuller and systemic mean arterial pressure improved to greater than 65 mm Hg. Thoracentesis was performed and pleural effusion evacuated resulting in A-profile on lung examination. Subsequently, the patient was intubated while breathing spontaneously and pericardial window was performed. In accordance with Surviving Sepsis Guidelines tissue perfusion markers were followed throughout the case, and goals of resuscitation are stated in the box on the far right.

Source: Bughrara, N., Diaz-Gomez, J. L. & Pustavoitau, A. Perioperative Management of Patients with Sepsis and Septic Shock, Part II: Ultrasound Support for Resuscitation. *Anesthesiol Clin* 38, 123–134 (2020).